

# Autologous Tooth Graft for Maxillary Sinus Augmentation: A Multicenter Clinical Study

Elio Minetti<sup>1,2</sup>, Andrea Palermo<sup>1,3,4</sup>, Marcello Contessi<sup>5</sup>, Ugo Gambardella<sup>6</sup>, Johannes H. Schmitz<sup>2</sup>, Edoardo Giacometti<sup>7,8</sup>, Martin Celko<sup>9,10</sup>, Paolo Trisi<sup>11,12</sup>

<sup>1</sup>Visiting Professor University of Bari "Aldo Moro", Bari, <sup>2</sup>Private Practice, Milan Italy, <sup>3</sup>Associate Professor in implant Dentistry, College of Medicine and Dentistry Birmingham, England, <sup>4</sup>Private Practice, Lecce, <sup>5</sup>Private Practice, Trieste, <sup>6</sup>Private Practice, Seriate, <sup>7</sup>Visiting Professor University of Genoa, <sup>8</sup>Private Practice, Turin, Italy, <sup>9</sup>Visiting Professor Olomouc University, <sup>10</sup>Private Practice Hradec Kralove, Czech Republic, <sup>11</sup>Biomaterial Clinical and Histological Research Association, <sup>12</sup>Private Practice, Pescara, Italy

## Abstract

**Aim:** The aim of this pilot study was to assess the performance of autologous tooth matrix, used as a graft material for maxillary sinus augmentation, after at least 1-year of follow-up. **Settings and Design:** The patients included in this prospective case series study were treated in four clinical centers using standardized clinical procedures. **Materials and Methods:** Patients with atrophic posterior maxilla in need of sinus augmentation before rehabilitation with implant-supported prostheses, and with compromised teeth to be extracted, were included. The extracted tooth was cleaned and processed by a recently introduced automated device, which allows fragmentation and partial demineralization of the tooth matrix, and used as a graft material for sinus augmentation. A covering membrane was used to protect the graft. Implants were placed after 6 months of healing. Five bone biopsies of the grafted sites were taken at the time of implant surgery, for histological analysis. Implants were followed for at least 1 year after placement. Cone-beam computed tomography and/or standardized periapical radiographs were used to assess the ridge height before and after grafting, up to 1-year postimplantation. **Statistical Analysis:** Descriptive statistics were used to synthesize the results, using mean values and standard deviations. **Results:** Twenty-three patients (9 males, mean age at surgery  $57.1 \pm 9.4$  years) were treated and 40 implants were placed in grafted sites. Residual ridge height was  $5.22 \pm 2.04$  mm and increased to  $14.72 \pm 2.83$  mm after grafting. One implant failed during healing phase. Cumulative implant survival rate was 97.5% after  $19.1 \pm 8.0$  months of follow-up (range 12.3–44.1 months). After 6 months of healing, the graft height appeared stable. No signs of sinus infection were present. The histologic analysis revealed neither inflammatory nor infective reaction against tooth graft. Granules appeared surrounded by newly formed bone and partially resorbed, indicating ongoing remodeling. **Conclusion:** Autologous human tooth matrix can be successfully used as graft material in sinus augmentation procedure.

**Keywords:** Bone regeneration, dentin graft, dentin matrix, oral implantology, sinus lift, tooth graft

## INTRODUCTION

One of the most popular techniques for the rehabilitation of atrophic maxilla with implant-supported restorations, when the available bone volume is insufficient to install standard dental implants, is maxillary sinus augmentation. The sinus floor elevation technique for grafting the floor of the maxillary sinus was first presented in 1977 by Tatum and first published in 1980 by Boyne and James.<sup>[1]</sup> Maxillary sinus augmentation is a predictable and well-documented method of grafting bone and bone substitutes for implant placement in the posterior maxilla.<sup>[2]</sup> The classical sinus lift procedure consists of the creation of a window in the lateral maxillary sinus bone wall.<sup>[3]</sup> This window exposes the Schneiderian membrane, which is then carefully detached from the bony wall and elevated

to forming the new sinus floor. Then, the space coronal to this lifted membrane is filled with graft material. Eventually, a resorbable membrane can be placed before suturing, to protect the healing site and avoid graft displacement.<sup>[3-6]</sup> Many evidence-based studies, systematic reviews, and meta-analyses demonstrated that maxillary sinus augmentation is associated with a high implant and prosthesis survival/success rate, also in the medium–long term.<sup>[7-13]</sup> The residual bone height and width, and the use of covering membranes to protect the graft,

**Address for correspondence:** Dr. Elio Minetti,  
Viale Pisa 10, 20146 Milano, Italy.  
E-mail: [elio.minetti@gmail.com](mailto:elio.minetti@gmail.com)

This is an open access journal, and articles are distributed under the terms of the Creative Commons Attribution-NonCommercial-ShareAlike 4.0 License, which allows others to remix, tweak, and build upon the work non-commercially, as long as appropriate credit is given and the new creations are licensed under the identical terms.

**For reprints contact:** [reprints@medknow.com](mailto:reprints@medknow.com)

**How to cite this article:** Minetti E, Palermo A, Contessi M, Gambardella U, Schmitz JH, Giacometti E, *et al.* Autologous tooth graft for maxillary sinus augmentation: A multicenter clinical study. *Int J Growth Factors Stem Cells Dent* 2019;2:45-51.

### Access this article online

#### Quick Response Code:



**Website:**  
[www.cellsindentistry.org](http://www.cellsindentistry.org)

**DOI:**  
10.4103/GFSC.GFSC\_13\_19

were among the factors mostly affecting the prognosis of the treatment, while no detrimental effect was demonstrated by the occurrence of Schneiderian membrane perforation.<sup>[14,15]</sup> In addition, no clear superiority was demonstrated by any of the numerous types of graft materials that have been used over the years.<sup>[16,17]</sup> Although autogenous bone has long been considered the “gold standard” because of its osteogenic, osteoconductive, and osteoinductive properties, it may have some drawbacks, such as donor site morbidity, limited availability, and, in some cases, high resorption rate.<sup>[18]</sup>

In the recent years, the use of dentin matrix from autologous extracted teeth has emerged as a promising alternative material to promote bone healing in intraoral defects.<sup>[19-23]</sup>

Indeed, the tooth grafting procedure has been introduced by Yeomans and Urist and Bang and Urist, more than 50 years ago, when they discovered the osteoinduction potential of demineralized dentin matrix.<sup>[24,25]</sup> More recently, Bessho *et al.* demonstrated the presence of bone morphogenetic proteins (BMPs) in the human dentin matrix. In particular, it was observed ectopic bone formation and osteoblasts presence in the rat muscle after demineralized human dentin matrix graft.<sup>[26]</sup>

Early experimental research showed that both bone tissue and dentin matrix contained specific molecules, essential to bone regeneration, such as BMPs, and other bioactive growth factors, such as transforming growth factor-beta.<sup>[27]</sup> Some authors theorized that the demineralization process allows better bone augmentation than nondemineralized dentin, probably because the availability of these molecules increases with matrix demineralization.<sup>[28]</sup>

Moreover, the chemical composition of bone and dentin is quite similar, consisting of an inorganic portion made of hydroxyapatite and an organic one, mainly composed of collagen type 1 and other secondary proteins.<sup>[29]</sup>

The effectiveness and safety of autogenous partially demineralized tooth matrix-prepared onsite, for clinical application in bone regeneration procedures related to implant dentistry, including socket preservation, alveolar ridge augmentation, and maxillary sinus floor augmentation were recently highlighted in human studies.<sup>[30,31]</sup>

An innovative medical device able to process extracted teeth, producing a suitable graft material, was introduced in the market. Such device ensures completely automated disinfection, grinding, and demineralizing processes avoiding human manipulation of the process.

A preliminary case series reported successful clinical outcomes and bone regeneration after autologous tooth grafting using this new device, demonstrating complete filling of the bone defects, in the absence of complications.<sup>[32]</sup>

The aim of this study was to assess the clinical, radiographic, and histological performance of autologous tooth matrix, used as a graft material for maxillary sinus augmentation.

## MATERIALS AND METHODS

All the procedures employed in the present study were in accordance with the ethical standards embedded in the Declaration of Helsinki 1975, as revised in 2000. No ethical approval was needed as there were no experimental procedures: standard protocols were followed and all materials and devices used are currently present in the market. This report was written by following the Strengthening the Reporting of Observational studies in Epidemiology guidelines for cohort studies.

All patients considered for inclusion in the study were examined and treated between February 2016 and October 2018 in four dental clinics located in Northern Italy and Czech Republic. Four operators with extensive experience in implant dentistry and maxillary sinus augmentation performed the surgical procedures. All patients signed written informed consent form before being included in the study.

### Inclusion criteria

General inclusion criteria were those commonly adopted in the four clinics: patients aged at least 18 years, with a good general health condition, and able to undergo surgical and restorative procedures (ASA-1 and ASA-2). Specific criteria were patients with edentulous posterior maxilla, and residual ridge insufficient for the placement of standard dental implants (at least 10-mm long); patients with residual ridge height at the intended implantation site no greater than 8 mm; and patients with one or more compromised teeth to be extracted before or simultaneously to sinus augmentation procedure. The reason for extraction had to be periodontal disease or caries. In case of caries, it had to involve less than one-third of the tooth.

### Exclusion criteria

Subjects were excluded if they were current heavy smokers (more than 10 cigarettes/day) or if they had uncontrolled systemic conditions causing healing impairment, i.e., diabetes mellitus, cancer, AIDS, bone metabolic diseases, patients taking systemic corticosteroids, immunosuppressive agents, radiation therapy, and/or chemotherapy within the past 6 months. Subjects taking intramuscular or intravenous bisphosphonates or who had allergies or sensitivity to alginate, latex, collagen, or acrylic were also excluded, as were pregnant, lactating, or intending to become pregnant women, or those participating in other clinical intervention studies. Patients unwilling or unavailable to attend the standard scheduled follow-ups were excluded. Teeth that underwent root canal treatment, as well as teeth with caries involving more than one-third of the tooth, could not be processed to obtaining graft material.

### Presurgical procedures

A preliminary clinical and radiographic examination was made before the surgical procedures. All patients underwent a session of professional oral hygiene 2 weeks before surgery. In addition, patients were instructed about standard oral hygiene

procedures and were prescribed with chlorhexidine 0.2% mouthrinse, twice a day for 2 weeks for plaque control.

A complete diagnostic radiographic examination with cone-beam computed tomography (CBCT) scans and conventional periapical or panoramic radiographs was performed, to assess the width and height of the residual alveolar process and the maxillary sinus dimension.

### Surgical procedures and follow-up

Antibiotic prophylaxis (amoxicillin and clavulanic acid 1 g) was administered 1 hour before intervention. Extraction of the compromised tooth/teeth was performed before sinus surgery, and teeth were processed using a specific device (Tooth Transformer [TT] S.r.l., Milan, Italy) to produce dentin matrix graft. After local anesthesia with articaine 4% + adrenaline 1:100,000, a mucoperiosteal full-thickness buccal flap was elevated to expose the lateral maxillary sinus wall. The extension of the sinus was determined referring to the CBCT scans. A lateral window was created using an ultrasonic device. The Schneiderian membrane was carefully detached starting from the mesial wall and elevated using appropriate membrane elevators. The absence of membrane perforations was assessed.

The sinus was filled with particulate dentin matrix grafts obtained with the TT.

The cortical osteotomy was then covered with absorbable membranes. The covering membrane extended 2–3 mm beyond window margins. Afterward, the flap was repositioned to stabilize soft tissue and was sutured. Amoxicillin (1000 mg b.i.d. for 6 days), or clindamycin (300 mg q.i.d. for 6–7 days) for subjects with penicillin allergies, was prescribed. At 1-week postsurgery, the sutures were removed.

### Procedure to obtaining tooth graft

The whole procedure to obtaining tooth graft was described previously.<sup>[29]</sup> Briefly, the extracted tooth was first cleaned from residual calculus using a piezoelectric instrument. The root surface was polished using diamond burs under abundant irrigation in order to carefully remove any filling materials (e.g., gutta-percha, composite) from the tooth. The tooth was then cut in small pieces, which were inserted into the mill. A box containing disposable solutions was placed in the device in a specific position. These solutions ensure dentin and enamel demineralization with release of BMP-2 and collagen, as well as thorough decontamination. After 25 min, demineralized tooth graft was ready to be used in the patient's mouth.

### Implant placement

The dental implants were placed after 6 months of healing according to the standardized surgical procedures, as indicated by the implant manufacturers.

### Histological and histomorphometric analysis

At the time of implant placement, biopsies were taken in five cases, in the region of the augmented sites, for histological analysis. The

samples were taken crestally before implant insertion, using graduated trephine drills (3–6 mm external diameter), under copious sterile saline irrigation. Biopsy sampling was done in correspondence with the implant site preparation and should not be considered additional surgical maneuver respect to the standard therapy.

Biopsies were carefully washed and fixed in 10% buffered formalin for 48 h at room temperature. Then, the samples were sent to the laboratory.

Each sample was dehydrated by a series of solutions with increasing alcohol concentration, up to pure alcohol and then infiltrated into methacrylic resin. After the light-curing of the resin, the sample was processed to obtain nondecalcified sections, using a disk abrasion system (LS2-Remet, Bologna) and a diamond disk cutting system (Micromet-Remet, Bologna).

In the first phase, the inclusion in resin is abraded to eliminate the resin component that covers the sample and the area of the biopsy to be observed was thus brought to the surface. Then, the surface was glued to a showcase with cyanoacrylate-based adhesives. Subsequently, cutting with high speed and cooling diamond blade is performed, to obtain a sample of about 200  $\mu$  thick, which was then thinned by abrasion. Each sample is then abraded reducing the thickness down to about 40–50  $\mu$ . At this point, the slide was polished with polishing papers and colored with basic fuchsin and blue toluidine for the final observation under light and polarized light microscopy.

For histomorphometric measurements, the histological images obtained from the transmitted light microscope were digitized through a digital camera and analyzed by means of an image analysis software IAS 2000. For each sample were calculated: BV% = Percentage of residual bone volume with the exclusion of medullary tissues; Graft% = Percentage of the remaining graft, excluding bone and marrow; VB% = Percentage of vital bone with exclusion of the bone marrow and the residual graft.

### Prosthesis delivery and follow-up

The prosthetic phase occurred after 5–6 months of implant placement, following the standard procedures adopted in each clinical center. Patients were recalled at 6 and 12 months after prosthesis delivery for standard clinical and radiographic controls.

The outcome variables were:

1. Implant survival, evaluated based on the following criteria: presence of the implant in the patient's mouth, absence of peri-implant radiolucency, no recurrence or persistent peri-implant infection and no complaint of pain and of neuropathies or paresthesia
2. Prosthesis success, defined by the presence of functional prosthesis in patient's mouth with no mechanical complications
3. Histomorphometric parameters from biopsies analysis.

## Statistical analysis

Patients' data were collected and stored on a specific datasheet (Microsoft Excel, Microsoft Corp., Redmond, WA, USA). Simple descriptive statistics were used, presenting the sample characteristics and the outcomes using mean values and standard deviations.

## RESULTS

Twenty-three subjects (9 men and 14 women) with a mean age at surgery of  $57.1 \pm 9.4$  years (range 40–76 years) were enrolled and treated following the described protocol. Four patients were smokers. One had a previous history of breast cancer.

The average dimension of the sinus was vertical  $9.47 \pm 3.45$  mm (range 6–18 mm), buccopalatal  $10.00 \pm 2.22$  mm (range 8–14 mm), and mesiodistal  $11.69 \pm 5.29$  mm (range 6–25 mm).

The mean residual ridge height at the intended implantation site was  $5.22 \pm 2.04$  mm (range 2.1–8.0 mm).

Twenty-three teeth, accounting for 52 roots (on the average 2.26 roots per each patient), were extracted and used for preparing the tooth graft. Nineteen teeth were nonvital and four were vital. Nine teeth were sound and 14 infected. In 13 cases, only root dentin was used, and in 10 cases also, enamel was processed.

The graft was covered with absorbable collagen membranes in 18 cases (Bego Collagen Membrane [porcine pericardium], Bego, Implant Systems, Bremen, Germany, in 16 cases; Biogide®, Geistlich Pharma, Wolhusen, Switzerland, in two cases). In the remaining cases, the graft was covered with a membrane made of a plasma rich in growth factors (PRGF®-Endoret, BTI Biotechnology Institute, Vitoria, Alava, Spain; 3 cases) or platelet-rich fibrin (A-PRF™, PRF Process, Nice, France; 2 cases). After grafting, the mean bone height was  $14.72 \pm 2.83$  mm (range 9.5–20.65 mm). The mean increase respect to baseline was  $9.50 \pm 2.70$  mm (range 5.0–15.14 mm). A total of 40 implants were placed. Four implant types of four different companies were used: Visio® One (CEA MEDICAL SA, Geneva, Switzerland;  $n = 30$ ), External Hex (Biomet 3i, Palm Beach Gardens, FL, USA;  $n = 5$ ), BTI Interna (BTI Biotechnology Institute, Vitoria, Alava, Spain;  $n = 4$ ), SLActive RN Tissue Level (Straumann Holding AG, Basel, Switzerland;  $n = 1$ ).

The mean follow-up after implant placement was  $19.1 \pm 8.0$  months (range 12.3–44.1 months). The follow-up for the graft was 6 months longer. Throughout the healing period, hard and soft tissues were stable. The healing of soft tissues after grafting procedures was free of complications. Figures 1 and 2 are panoramic radiographs of a case before grafting and at 6 months of healing, soon after implant placement.

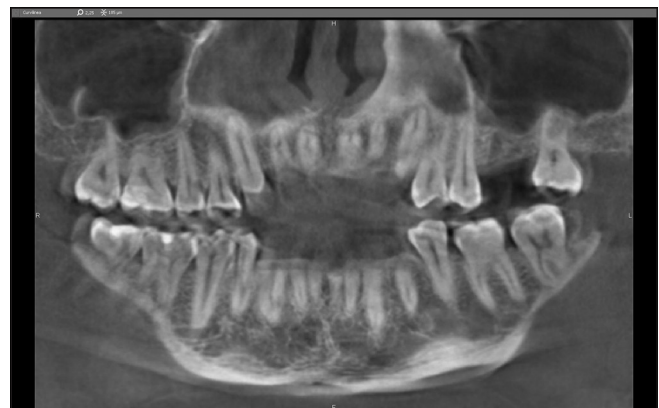During the follow-up, one implant was lost. It showed suppuration after 3 months of placement. The implant was

replaced without compromising prosthesis function. Implant and prosthesis survival after 1 year were 97.5% and 100%. After 1 year from implant placement, peri-implant bone levels and graft height were stable.

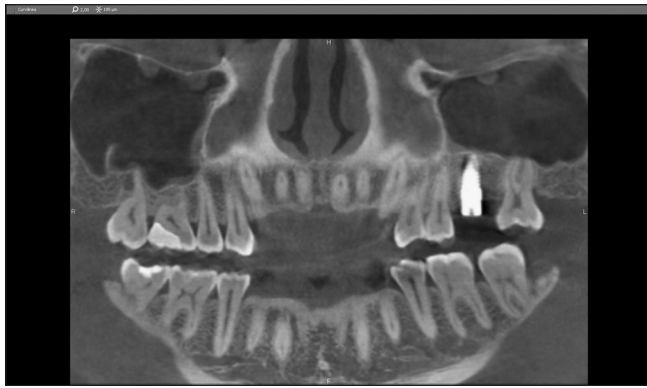The results of the histomorphometric analysis of the graft biopsies showed that the mean BV% was  $36.28\% \pm 9.77\%$ , the mean residual graft% was  $14.61\% \pm 9.37\%$  and the VB% was  $21.51\% \pm 8.61\%$  [Figures 3-5]. No inflammatory reactions around dentin granules were observed. The graft appeared to be subjected to physiological bone remodeling, demonstrating an excellent integration with the host tissues. No difference was found, either from a clinical or a histological standpoint, between originally infected and noninfected teeth, and between vital and nonvital teeth.

## DISCUSSION

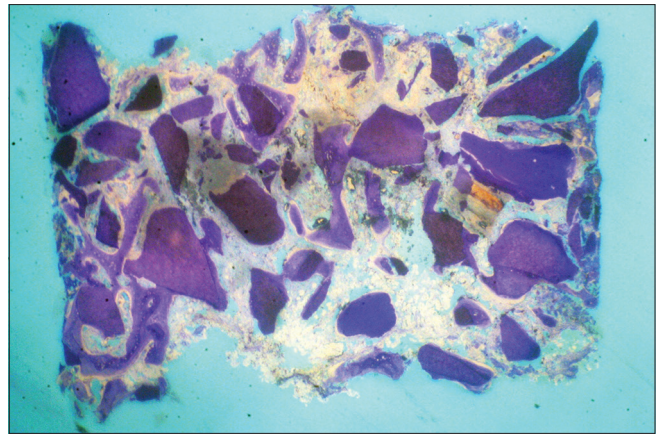
This study evaluated hard and soft tissue healing and implant survival rate after maxillary sinus augmentation performed using an autologous graft made of demineralized dentin/enamel matrix. This graft derives from the extracted patient's tooth and is produced by processing the tooth itself with a recently introduced device, able to shred and decontaminate dental elements and transform them into a grafting material usable for the treatment of different types of bone defects in oral surgery procedures. The results of this study suggested that autologous tooth matrix is a feasible grafting material for sinus augmentation, being the clinical and histomorphometric outcomes in line with the current literature.<sup>[7-13,16,17,33]</sup> This study has several limitations that should be taken into account. First, the number of patients, as well as the follow-up duration, is relatively limited. However, also, other studies presenting histologic and histomorphometric results of graft materials had similar sample size.<sup>[34-37]</sup> Second, the study was not comparative. This was a preliminary study, aiming at evaluating the feasibility and safety of the tooth graft as a sinus grafting material. Since the results were satisfactory, the authors will plan to perform evidence-based comparative



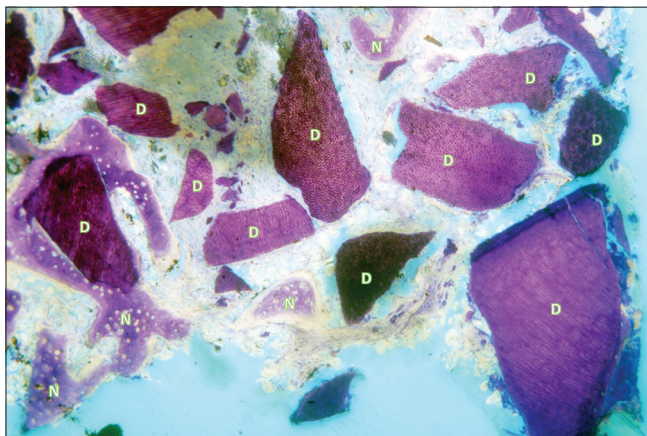
**Figure 1:** Panoramic view from cone-beam computed tomography scan taken after extraction of the first upper left molar and before sinus lift procedure. The residual height at the intended molar implantation site was 5.37 mm



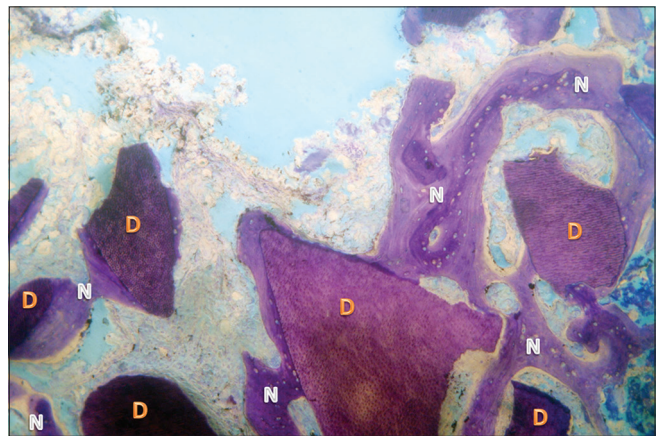
**Figure 2:** Panoramic view from cone-beam computed tomography scan taken 6 months after sinus augmentation procedure, soon after implant placement. The margin of biopsy is visible around the apical portion of the implant



**Figure 3:** Overview of a biopsy at low magnification: Dentin matrix granules (darker stain) and newly formed bone were visible (Toluidine Blue,  $\times 8$ )



**Figure 4:** Newly formed bone trabeculae (N) and dentin matrix graft particles (D) were observed. On the left side, a granule is almost completely surrounded by new bone (Toluidine Blue,  $\times 25$ )



**Figure 5:** Dentin matrix graft granules (D) appeared well integrated into the new bone (N). The dentin granules showed numerous characteristic dots that correspond to dentinal tubules (Toluidine Blue,  $\times 50$ )

studies in the near future, to confirm the outcomes obtained using the TT device.

The use of tooth derivatives such as dentin and/or enamel as potential graft materials for the treatment of bone defects have emerged in the last decades. The strong points in favor of using such material are as follows: it is totally autogenous; it does not require an additional surgical site for harvesting bone graft; the dentin structure and composition is very similar to that of bone; it has been shown to contain BMP-2, that is made available by the demineralization procedure, giving to the material osteoinductive properties (in addition to the osteoconductive features, provided by the porous three-dimensional matrix). Furthermore, the idea of recycling compromised teeth that need to be extracted, instead of discarding them, thereby avoiding the use of expensive heterologous or synthetic bone substitutes, is expected to be well-accepted by patients.

Several studies pointed out that the demineralization process is highly critical to determine tooth graft properties.<sup>[29-31]</sup> This process is required to expose and make available the growth and differentiation factors embedded in the

hydroxyapatite crystals, especially the BMPs, which have osteoinductive properties.<sup>[24-26]</sup> In fact, different exposure times, combinations and concentrations of the strong acids used for demineralization, may produce grafts with different biological activity, as suggested by previous *in vivo* studies on ectopic<sup>[38-42]</sup> and orthotopic models.<sup>[43-45]</sup> In a recent review, Kim *et al.* concluded that the osteoinductive properties of dentin graft might depend on different acid treatment protocols, underlying the importance of this process.<sup>[46]</sup>

The physical-chemical and biochemical features of dentin and enamel matrix obtained after processing teeth derivatives with the TT device have been described in a recent *in vitro* study.<sup>[47]</sup> That study found that the biocompatibility of demineralized dentin is even higher than the more popular anorganic bovine bone, and that demineralization increases BMP-2 and collagen type I bioavailability as compared with nondemineralized tooth derivatives. The tooth graft also proved to have high wettability that allows easy handling and positioning on the defect site. In addition, the study found that the sterilization process accomplished by the TT device is highly effective as

no microbial contamination was detected on the processed samples. The study concluded that demineralized tooth matrix represents a suitable biomaterial for bone regeneration and replacement.<sup>[47]</sup>

In a previous clinical study, the same device was used in a series of 15 patients, mostly for postextraction alveolar socket preservation, reporting favorable clinical and radiographic results, in the absence of complications and adverse events.<sup>[32]</sup>

As there is a wide availability of teeth that every day are extracted and discarded in dental offices, this new device may represent an advanced system in the area of tissue engineering, with a strong potential to produce suitable substrates for bone regeneration procedures.

In recent years, two systematic reviews of the literature were published, assessing the reliability of autogenous tooth graft material applied to bone augmentation procedures for alveolar ridge reconstruction.<sup>[27,48]</sup> Both reviews identified only six studies that used autogenous teeth for bone grafting of alveolar deficiencies. The studies had different design, from randomized to retrospective, and collectively showed limited available evidence on the efficacy of such material.

In one of these reviews, the authors reported an implant survival rate of 97.7% (of a total of 182 implants analyzed), in line with the results of the present study, and also, histological results were very similar to those herein reported.

In spite of the limited number of studies, sample size, and evidence level, all these investigations showed very promising results, suggesting that autogenous tooth matrix can be considered a feasible alternative to more popular biomaterials. The results of these reviews are encouraging and underline the need for performing further investigations to estimate the true effect of using processed tooth as bone graft material.

## CONCLUSION

Demineralized autogenous teeth represent a feasible and safe substrate for grafting the maxillary sinus, due to osteoconductive and osteoinductive properties.

Future studies with long follow-up period are needed to get more insight on the potential of demineralized tooth autografts.

## Financial support and sponsorship

Nil.

## Conflicts of interest

Elio Minetti acts as consultant for TT Tooth Transformer SRL (Via Washington, 59 – Milan, Italy).

## REFERENCES

1. Boyne PJ, James RA. Grafting of the maxillary sinus floor with autogenous marrow and bone. *J Oral Surg* 1980;38:613-6.
2. Sanz M, Donos N, Alcoforado G, Balmer M, Gurzawska K, Mardas N, *et al.* Therapeutic concepts and methods for improving dental implant outcomes. Summary and consensus statements. The 4<sup>th</sup> EAO Consensus Conference 2015. *Clin Oral Implants Res* 2015;26 Suppl 11:202-6.

3. Wallace SS, Tarnow DP, Froum SJ, Cho SC, Zadeh HH, Stoupe J, *et al.* Maxillary sinus elevation by lateral window approach: Evolution of technology and technique. *J Evid Based Dent Pract* 2012;12:161-71.
4. Starch-Jensen T, Jensen JD. Maxillary sinus floor augmentation: A review of selected treatment modalities. *J Oral Maxillofac Res* 2017;8:e3.
5. Ohayon L, Taschieri S, Corbella S, Del Fabbro M. Maxillary sinus floor augmentation using biphasic calcium phosphate and a hydrogel polyethylene glycol covering membrane: An histological and histomorphometric evaluation. *Implant Dent* 2016;25:599-605.
6. Ohayon L, Taschieri S, Friedmann A, Del Fabbro M. Bone graft displacement after maxillary sinus floor augmentation with or without covering barrier membrane: A retrospective computed tomographic image evaluation. *Int J Oral Maxillofac Implants* 2019;34:681-91.
7. Wallace SS, Froum SJ. Effect of maxillary sinus augmentation on the survival of endosseous dental implants. A systematic review. *Ann Periodontol* 2003;8:328-43.
8. Del Fabbro M, Testori T, Francetti L, Weinstein R. Systematic review of survival rates for implants placed in the grafted maxillary sinus. *Int J Periodontics Restorative Dent* 2004;24:565-77.
9. Del Fabbro M, Rosano G, Taschieri S. Implant survival rates after maxillary sinus augmentation. *Eur J Oral Sci* 2008;116:497-506.
10. Pjetursson BE, Tan WC, Zwahlen M, Lang NP. A systematic review of the success of sinus floor elevation and survival of implants inserted in combination with sinus floor elevation. *J Clin Periodontol* 2008;35:216-40.
11. Del Fabbro M, Wallace SS, Testori T. Long-term implant survival in the grafted maxillary sinus: A systematic review. *Int J Periodontics Restorative Dent* 2013;33:773-83.
12. Antonoglou GN, Stavropoulos A, Samara MD, Ioannidis A, Benic GI, Papageorgiou SN, *et al.* Clinical performance of dental implants following sinus floor augmentation: A systematic review and meta-analysis of clinical trials with at least 3 years of follow-up. *Int J Oral Maxillofac Implants* 2018;33:e45-e65.
13. Starch-Jensen T, Aludden H, Hallman M, Dahlin C, Christensen AE, Mordenfeld A. A systematic review and meta-analysis of long-term studies (five or more years) assessing maxillary sinus floor augmentation. *Int J Oral Maxillofac Surg* 2018;47:103-16.
14. Al-Moraissi E, Elsharkawy A, Abotaleb B, Alkebsi K, Al-Motwakel H. Does intraoperative perforation of Schneiderian membrane during sinus lift surgery causes an increased risk of implants failure? A systematic review and meta regression analysis. *Clin Implant Dent Relat Res* 2018;20:882-9.
15. Testori T, Weinstein T, Taschieri S, Wallace SS. Risk factors in lateral window sinus elevation surgery. *Periodontol* 2000 2019;81:91-123.
16. Rickert D, Slater JJ, Meijer HJ, Vissink A, Raghoobar GM. Maxillary sinus lift with solely autogenous bone compared to a combination of autogenous bone and growth factors or (solely) bone substitutes. A systematic review. *Int J Oral Maxillofac Surg* 2012;41:160-7.
17. Al-Moraissi EA, Alkhatari AS, Abotaleb B, Altairi NH, Del Fabbro M. Do osteoconductive bone substitutes result in similar bone regeneration for maxillary sinus augmentation when compared to osteogenic and osteoinductive bone grafts? A systematic review and frequentist network meta-analysis. *Int J Oral Maxillofac Surg* 2019. pii: S0901-5027 (19) 31163-4.
18. von Arx T, Hardt N, Wallkamm B. The TIME technique: A new method for localized alveolar ridge augmentation prior to placement of dental implants. *Int J Oral Maxillofac Implants* 1996;11:387-94.
19. Pang KM, Um IW, Kim YK, Woo JM, Kim SM, Lee JH. Autogenous demineralized dentin matrix from extracted tooth for the augmentation of alveolar bone defect: A prospective randomized clinical trial in comparison with anorganic bovine bone. *Clin Oral Implants Res* 2017;28:809-15.
20. Kim YK, Kim SG, Yun PY, Yeo IS, Jin SC, Oh JS, *et al.* Autogenous teeth used for bone grafting: A comparison with traditional grafting materials. *Oral Surg Oral Med Oral Pathol Oral Radiol* 2014;117:e39-45.
21. Gharpure AS, Bhatavadekar NB. Clinical efficacy of tooth-bone graft: A systematic review and risk of bias analysis of randomized control trials and observational studies. *Implant Dent* 2018;27:119-34.
22. Del Canto-Díaz A, de Elio-Oliveros J, Del Canto-Díaz M,

- Alobera-Gracia MA, Del Canto-Pingarrón M, Martínez-González JM. Use of autologous tooth-derived graft material in the post-extraction dental socket. Pilot study. *Med Oral Patol Oral Cir Bucal* 2019;24:e53-60.
23. Cardaropoli D, Nevins M, Schupbach P. New bone formation using an extracted tooth as a biomaterial: A case report with histologic evidence. *Int J Periodontics Restorative Dent* 2019;39:157-63.
  24. Yeomans JD, Urist MR. Bone induction by decalcified dentin implanted into oral, osseous and muscle tissues. *Arch Oral Biol* 1967;12:999-1008.
  25. Bang G, Urist MR. Bone induction in excavation chambers in matrix of decalcified dentin. *Arch Surg* 1967;94:781-9.
  26. Bessho K, Tanaka N, Matsumoto J, Tagawa T, Murata M. Human dentin-matrix-derived bone morphogenetic protein. *J Dent Res* 1991;70:171-5.
  27. Nakashima M. Bone morphogenetic proteins in dentin regeneration for potential use in endodontic therapy. *Cytokine Growth Factor Rev* 2005;16:369-76.
  28. Rijal G, Shin HI. Human tooth-derived biomaterial as a graft substitute for hard tissue regeneration. *Regen Med* 2017;12:263-73.
  29. Kim YK, Kim SG, Oh JS, Jin SC, Son JS, Kim SY, *et al.* Analysis of the inorganic component of autogenous tooth bone graft material. *J Nanosci Nanotechnol* 2011;11:7442-5.
  30. Minamizato T, Koga T, I T, Nakatani Y, Umebayashi M, Sumita Y, *et al.* Clinical application of autogenous partially demineralized dentin matrix prepared immediately after extraction for alveolar bone regeneration in implant dentistry: A pilot study. *Int J Oral Maxillofac Surg* 2018;47:125-32.
  31. Kim SY, Kim YK, Park YH, Park JC, Ku JK, Um IW, *et al.* Evaluation of the Healing Potential of Demineralized Dentin Matrix Fixed with Recombinant Human Bone Morphogenetic Protein-2 in Bone Grafts. *Materials (Basel)*. 2017;10: (9) pii: E1049. doi: 10.3390/ma10091049.
  32. Minetti E, Berardini M, Trisi P. A new tooth processing apparatus allowing to obtain dentin grafts for bone augmentation: The tooth transformer. *Open Dent J* 2019;13:6-14.
  33. Corbella S, Taschieri S, Weinstein R, Del Fabbro M. Histomorphometric outcomes after lateral sinus floor elevation procedure: A systematic review of the literature and meta-analysis. *Clin Oral Implants Res* 2016;27:1106-22.
  34. Froum SJ, Wallace SS, Tarnow DP, Cho SC. Effect of platelet-rich plasma on bone growth and osseointegration in human maxillary sinus grafts: Three bilateral case reports. *Int J Periodontics Restorative Dent* 2002;22:45-53.
  35. Aimetti M, Romano F, Dellavia C, De Paoli S. Sinus grafting using autogenous bone and platelet-rich plasma: Histologic outcomes in humans. *Int J Periodontics Restorative Dent* 2008;28:585-91.
  36. Anitua E, Prado R, Orive G. Bilateral sinus elevation evaluating plasma rich in growth factors technology: A report of five cases. *Clin Implant Dent Relat Res* 2012;14:51-60.
  37. Taschieri S, Testori T, Corbella S, Weinstein R, Francetti L, Di Giancamillo A, *et al.* Platelet-rich plasma and deproteinized bovine bone matrix in maxillary sinus lift surgery: A split-mouth histomorphometric evaluation. *Implant Dent* 2015;24:592-7.
  38. Urist MR. Bone histogenesis and morphogenesis in implants of demineralized enamel and dentin. *J Oral Surg* 1971;29:88-102.
  39. Inoue T, Deporter DA, Melcher AH. Induction of cartilage and bone by dentin demineralized in citric acid. *J Periodontal Res* 1986;21:243-55.
  40. Murata M, Kawai T, Kawakami T, Akazawa T, Tazaki J, Ito K, *et al.* Human acid-insoluble dentin with BMP-2 accelerates bone induction in subcutaneous and intramuscular tissues. *J Ceram Soc Jpn* 2010;118:438-41.
  41. Bang G. Induction of heterotopic bone formation by demineralized dentin in guinea pigs: Antigenicity of the dentin matrix. *J Oral Pathol* 1972;1:172-85.
  42. Bang G. Induction of heterotopic bone formation by demineralized dentin: An experimental model in guinea pigs. *Scand J Dent Res* 1973;81:240-50.
  43. Jeong HR, Hwang JH, Lee JK. Effectiveness of autogenous tooth bone used as a graft material for regeneration of bone in miniature pig. *J Korean Assoc Oral Maxillofac Surg* 2011;37:375-9.
  44. Catanzaro-Guimarães SA, Catanzaro Guimarães BP, Garcia RB, Alle N. Osteogenic potential of autogenic demineralized dentin implanted in bony defects in dogs. *Int J Oral Maxillofac Surg* 1986;15:160-9.
  45. Gomes MF, dos Anjos MJ, Nogueira TO, Guimarães SA. Histologic evaluation of the osteoinductive property of autogenous demineralized dentin matrix on surgical bone defects in rabbit skulls using human amniotic membrane for guided bone regeneration. *Int J Oral Maxillofac Implants* 2001;16:563-71.
  46. Kim YK, Lee J, Um IW, Kim KW, Murata M, Akazawa T, *et al.* Tooth-derived bone graft material. *J Korean Assoc Oral Maxillofac Surg* 2013;39:103-11.
  47. Bono N, Tarsini P, Candiani G. Demineralized dentin and enamel matrices as suitable substrates for bone regeneration. *J Appl Biomater Funct Mater* 2017;15:e236-43.
  48. Ramanauskaitė A, Sahin D, Sader R, Becker J, Schwarz F. Efficacy of autogenous teeth for the reconstruction of alveolar ridge deficiencies: a Systematic review. *Clin Oral Investig* 2019;23:4263-87.